

Isolated Deep Venous Thrombosis: Implications for 2-Point Compression Ultrasonography of the Lower Extremity

Srikar Adhikari, MD, MS*; Wes Zeger, DO; Christopher Thom, MD; J. Matthew Fields, MD

*Corresponding Author. E-mail: sriadhikari@aol.com.

Study objective: Two-point compression ultrasonography focuses on the evaluation of common femoral and popliteal veins for complete compressibility. The presence of isolated thrombi in proximal veins other than the common femoral and popliteal veins should prompt modification of 2-point compression technique. The objective of this study is to determine the prevalence and distribution of deep venous thrombi isolated to lower-extremity veins other than the common femoral and popliteal veins in emergency department (ED) patients with clinically suspected deep venous thrombosis.

Methods: This was a retrospective study of all adult ED patients who received a lower-extremity venous duplex ultrasonographic examination for evaluation of deep venous thrombosis during a 6-year period. The ultrasonographic protocol included B-mode, color-flow, and spectral Doppler scanning of the common femoral, femoral, deep femoral, popliteal, and calf veins.

Results: Deep venous thrombosis was detected in 362 of 2,451 patients (14.7%; 95% confidence interval [CI] 13.3% to 16.1%). Thrombus confined to the common femoral vein alone was found in 5 of 362 cases (1.4%; 95% CI 0.2% to 2.6%). Isolated femoral vein thrombus was identified in 20 of 362 patients (5.5%; 95% CI 3.2% to 7.9%). Isolated deep femoral vein thrombus was found in 3 of 362 cases (0.8%; 95% CI -0.1% to 1.8%). Thrombus in the popliteal vein alone was identified in 53 of 362 cases (14.6%; 95% CI 11% to 18.2%).

Conclusion: In our study, 6.3% of ED patients with suspected deep venous thrombosis had isolated thrombi in proximal veins other than common femoral and popliteal veins. Our study results support the addition of femoral and deep femoral vein evaluation to standard compression ultrasonography of the common femoral and popliteal vein, assuming that this does not have a deleterious effect on specificity. [Ann Emerg Med. 2014;■:1-5.]

Please see page XX for the Editor's Capsule Summary of this article.

0196-0644/\$-see front matter

Copyright © 2014 by the American College of Emergency Physicians.

<http://dx.doi.org/10.1016/j.annemergmed.2014.10.032>

INTRODUCTION

Background and Importance

Duplex ultrasonography is the most useful and widely accepted imaging modality for the evaluation of lower-extremity deep venous thrombosis. Multiple studies have shown that it is highly sensitive and specific for diagnosing deep venous thrombosis.¹ The practice guidelines developed by American Institute of Ultrasound in Medicine recommend evaluation of common femoral, femoral (formerly called the superficial femoral vein), proximal deep femoral, popliteal, and proximal great saphenous veins for compressibility and obtaining of spectral Doppler waveforms of common femoral, external iliac, and popliteal veins.²

Point-of-care compression ultrasonography is increasingly used by emergency physicians for the evaluation of lower-extremity deep venous thrombosis.³⁻⁶ It is listed as one of the core emergency ultrasonographic applications in the most recent American College of Emergency Physicians

emergency ultrasonographic guidelines.⁷ It is widely available, easy to perform, and can be conducted rapidly at bedside to direct appropriate therapy in a timely fashion. The simplified 2-point compression technique focuses on the evaluation of common femoral and popliteal veins of the lower extremity for complete compressibility and does not include the use of color-flow and pulsed-wave Doppler.⁸

Bernardi et al⁹ compared 2-point compression ultrasonography (common femoral and popliteal veins) with whole-leg, color-coded, duplex, lower-extremity ultrasonography and found both strategies to be equivalent when used for the management of symptomatic patients with suspected deep venous thrombosis. In this study, patients with normal 2-point compression ultrasonography findings also underwent D-dimer testing. Patients with elevated D-dimer levels and a normal 2-point compression study result were scheduled for repeated ultrasonography within 1 week to rule out an isolated clot in locations other than the common femoral and

Editor's Capsule Summary*What is already known on this topic*

Bedside compression ultrasonography can identify deep venous thrombosis of the leg. Both 2- (common femoral and popliteal) and 3-point approaches are used.

What question this study addressed

What is the frequency of isolated deep venous thrombosis confined to the femoral and deep femoral veins, deep venous thromboses that could be missed by 2-point ultrasonography?

What this study adds to our knowledge

In this single-center retrospective study of full-leg ultrasonography conducted for standard care, 23 of 362 deep venous thromboses (6.3%) were outside the usual 2-point examination focus.

How this is relevant to clinical practice

A more extensive leg bedside ultrasonographic examination beyond the 2-point approach increases sensitivity for deep venous thrombosis, though the effect on diagnostic specificity and outcome is uncertain.

popliteal veins. Unfortunately, this approach has limitations in the emergency department (ED), such as inadequate compliance with follow-up. In a study conducted by McIlrath et al,¹⁰ patient compliance with follow-up ultrasonographic examinations 5 to 7 days after emergency physician-performed ultrasonographic examinations was extremely low. The specificity of elevated D-dimer level declines with increasing age, and these levels are elevated in the elderly and in numerous other acute and chronic conditions even in the absence of thrombosis.¹¹ Inclusion of D-dimer testing in the diagnostic evaluation of patients with normal 2-point compression ultrasonography results could result in unnecessary additional diagnostic testing, time, and expense. Furthermore, D-dimer testing in the ED requires a blood draw, adds additional expense, and takes time, all of which can lead to decreased patient throughput. Hence, we pursued the following research question: Should emergency physicians use an extended proximal compression ultrasonographic technique to assess for isolated thrombi in locations beyond the common femoral and popliteal veins? To answer this question, one must know the prevalence of isolated thrombi in lower-extremity veins not assessed by 2-point compression ultrasonography.

Goals of This Investigation

The objective of this study was to determine the prevalence and distribution of deep venous thrombi isolated to lower-extremity veins other than the common femoral and popliteal veins in ED patients with clinically suspected deep venous thrombosis.

MATERIALS AND METHODS**Study Design**

This was a retrospective study of all patients who received a lower-extremity venous duplex ultrasonographic examination in the ED during a 6-year period. The institutional review board approved this study.

Study Setting and Selection of Participants

This study took place at a Level I academic urban ED with an annual census of approximately 45,000 patients. The ED has a 3-year residency training program and an active emergency ultrasonographic education program. All adult patients (≥ 19 years) who received a comprehensive lower-extremity venous duplex ultrasonographic examination in the ED for evaluation of deep venous thrombosis were included in this study.

Patients were included in the study if they were treated in the ED and underwent a comprehensive lower-extremity venous duplex ultrasonographic examination for symptoms suspicious of deep venous thrombosis. Patients were evaluated by emergency medicine residents and attending physicians before receiving an ultrasonographic examination. Clinical gestalt was used to risk-stratify patients. The ultrasonographic examinations were performed by vascular surgery division sonographers. Board-certified vascular surgeons interpreted the ultrasonographic images and reported the final ultrasonographic findings. The ultrasonographic protocol included B-mode, color-flow, and spectral Doppler scanning of deep veins of the lower extremity. The common femoral vein, femoral vein, deep femoral vein, popliteal vein, and calf veins were evaluated, including venous confluences (saphenofemoral, femoral/deep femoral, saphenopopliteal, gastrocnemius, and tibial vein confluences). The veins were assessed for compressibility with extrinsic probe compressions in transverse plane. The veins were also evaluated for full-color filling by color-flow Doppler scanning, and spectral Doppler tracings were also obtained. The venous Doppler signals were assessed for spontaneity, respiratory variation, augmentation with a distal compression, and reflux with proximal compression or Valsalva's maneuver. An acute deep venous thrombosis was identified by the presence of a dilated vein, lack of compressibility, and absence of Doppler flow signals.

The hospital electronic database was queried to extract all the ED visits for the study period. For each ED visit, the electronic medical record was queried to determine the presence of a lower-extremity venous duplex ultrasonographic examination order during the ED encounter. Current Procedural Terminology code for lower-extremity venous duplex ultrasonographic examination was also used to identify ED patients who received a lower-extremity venous duplex ultrasonographic examination during the study period. To ensure that all eligible patients were enrolled in the study, the radiology examination database was also queried for all lower-extremity venous ultrasonographic examinations performed during the study period and cross-checked against ED encounter query. Medical records of all our subjects were reviewed by 3 physicians for final ultrasonographic reports. Data were collected independently by 3 physicians after a training session to standardize data collection strategies. A standardized data collection form was used for data abstraction. Any discrepancies in the data extraction were resolved through discussion and consensus. The ultrasonographic images archived in picture archiving and communication system were also reviewed to resolve discrepancies.

Primary Data Analysis

Descriptive analyses were performed with SAS (version 9.2; SAS Institute, Inc., Cary, NC). Continuous data were presented as means with SDs, and percentage frequency of occurrence with 95% confidence intervals (CIs). Interobserver agreement among data abstractors was assessed by κ analysis for location of the thrombus.

RESULTS

A total of 2,451 patients (women 1,595; men 856) underwent lower-extremity venous duplex ultrasonographic examinations. Interobserver agreement among chart reviewers was high for location of the thrombus ($\kappa=0.95$). The mean age of the patients was 60 years (SD 19 years). Superficial vein thrombosis was detected in 96 cases (3.9%; 95% CI 3.1% to 4.7%). Deep venous thrombosis was detected in 362 patients (14.7%; 95% CI 13.3% to 16.1%). The distribution of isolated proximal vein thrombi is summarized in the Figure. Thrombus confined to the common femoral vein alone was found in 5 of 362 cases (1.4%; 95% CI 0.2% to 2.6%). Isolated femoral vein thrombus was identified in 20 of 362 patients (5.5%; 95% CI 3.2% to 7.9%). Isolated deep femoral vein thrombus was found in 3 of 362 cases (0.8%; 95% CI -0.1% to 1.8%). Thrombus in the popliteal vein alone was identified in 53 of 362 cases (14.6%; 95% CI 11% to 18.2%).

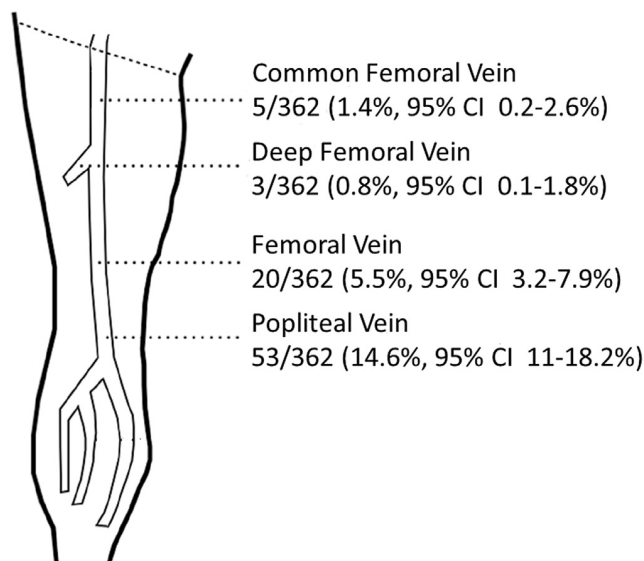


Figure. Distribution of isolated proximal vein thrombi.

Thrombus was present in more than 1 lower-extremity vein in a majority of patients. The patterns of thrombus location in different lower-extremity veins are summarized in the Table. No free-floating thrombi were reported. Sixteen cases were reported as technically difficult ultrasonographic examinations. Two of these patients had thrombus in deep veins.

LIMITATIONS

This study has several limitations, including its retrospective nature. It was conducted at a single academic institution, and results may not be generalizable to other

Table. Patterns of thrombus location in different lower-extremity veins.

Lower-Extremity Veins	Entire Sample (n=362), No. (%)
Common femoral vein	5 (1.4)
Femoral vein	20 (5.5)
Deep femoral vein	3 (0.8)
Popliteal vein	53 (14.6)
Common femoral+femoral veins	15 (4.1)
Common femoral+femoral+deep femoral veins	7 (1.9)
Common femoral+femoral+popliteal veins	28 (7.7)
Common femoral+deep femoral+popliteal veins	7 (1.9)
Common femoral+popliteal veins	3 (0.83)
Common femoral+femoral+deep femoral+popliteal veins	35 (9.6)
Femoral+deep femoral veins	1 (0.27)
Femoral+popliteal veins	56 (15.4)
Calf veins+proximal veins	71 (19.6)
Calf veins	58 (16)

settings. The study sample was chosen according to the accessibility of electronic medical records. The asymptomatic contralateral lower extremity was not routinely evaluated for deep venous thrombosis. Our study determined location of thrombus from the vascular surgery ultrasonographic reports. Although there was a high interrater reliability among data abstractors, it is possible that the vascular surgery division sonographers or vascular surgeons did not accurately or precisely code the distribution of thrombus, resulting in either overestimation or underestimation of distribution of thrombi in some cases. The data extractors were not blinded to the study hypothesis. However, we attempted to minimize the bias in retrospective data extraction by using a standardized data collection form. Medical records were not reviewed for additional diagnostic testing, disposition plan, hospital course, and follow-up visits. The information about demographics, symptoms, signs, and basic risk factors for all our study subjects was not collected. However, given that prevalence of deep venous thrombosis in our patients who underwent lower-extremity ultrasonography approximates that found in other studies, we believe our patients are similar to those of other studies and institutions.

DISCUSSION

In our study, a significant proportion of patients were found to have isolated thrombi in locations other than the common femoral and popliteal veins. Our study results differ from those of a previous study conducted by Cogo et al.¹² In this study, the investigators studied a large series of venograms and found that none of the patients with clinically suspected venous thrombosis had isolated thrombi in the femoral vein. In our cohort, the prevalence of thrombi isolated to femoral vein was 5.5%. As in our study, Frederick et al¹³ found the prevalence of thrombi isolated to the femoral vein without proximal extension to be 4.6% in cases of acute deep venous thrombosis. In addition, Maki et al¹⁴ reported that up to 22% of lower-extremity thrombi could be isolated to the femoral vein. These differences in prevalence may be related to the patient populations studied. Some studies included both symptomatic and asymptomatic patients, whereas others included only symptomatic patients. Regardless, exclusion of the femoral vein imaging with 2-point compression ultrasonography would have resulted in missing a significant number of isolated lower-extremity thrombi. Although there is no published acceptable threshold for identifying deep venous thrombosis, we believe that any pathology with the potential for life-threatening complications (such as venous thromboembolism) should be pursued while the patient is in the ED.

One major implication of our findings is that a significant proportion of patients have isolated thrombi in proximal veins other than common femoral and popliteal veins. The results of our study support the use of extended point-of-care compression ultrasonographic technique evaluating the common femoral vein, femoral vein, proximal deep femoral vein, and popliteal vein. We recommend compression of the proximal deep femoral vein because there is a small incidence (<1%) of isolated thrombus in this region. This modified technique is relatively simple, not time consuming, and can be taught to any physician with basic ultrasonographic skills. It requires only translation of the probe down from the common femoral vein over the femoral and proximal deep femoral veins to assess for compressibility. This modified evaluation does not require additional knowledge with regard to technique and should add only seconds to minutes to the ultrasonographic examination to help avoid missing isolated thrombi. We believe that this additional time required to evaluate femoral and proximal deep femoral veins is outweighed by the benefit of potentially finding an isolated clot one would have otherwise missed. The use of extended point-of-care compression ultrasonographic technique may decrease D-dimer testing and therefore decrease the incidence of false-positive D-dimer test results that would require whole-leg, color-coded, duplex, lower extremity ultrasonography. A large prospective randomized study comparing 2 techniques (extended point-of-care compression ultrasonography versus whole-leg, color-coded, duplex, lower-extremity ultrasonography) would be ideal to determine the role of extended point-of-care compression ultrasonography in the evaluation of patients with suspected deep venous thrombosis. Additionally, a future study should evaluate for potential risk factors associated with thrombi in locations such as the femoral or deep femoral veins.

In our study, 6.3% of ED patients with suspected deep venous thrombosis had isolated thrombi in proximal veins other than common femoral and popliteal veins. Our study results support the addition of femoral and deep femoral vein evaluation to standard compression ultrasonography of the common femoral and popliteal vein, assuming that this does not have a deleterious effect on specificity.

The authors acknowledge Ilir Frrokaj, MD, for his assistance with data collection.

Supervising editors: Jeffrey Kline, MD; Donald M. Yealy, MD

Author affiliations: From the Department of Emergency Medicine, the University of Arizona Medical Center, Tucson, AZ (Adhikari); the Department of Emergency Medicine, University of Nebraska

Medical Center, Omaha, NE (Zeger); and the Department of Emergency Medicine, Thomas Jefferson University, Philadelphia, PA (Thom, Fields).

Author contributions: SA and WZ conceived and designed the study and were responsible for data collection and data entry. All authors participated in data analysis. SA drafted the article, and WZ, CT, and MJF contributed substantially to its revision. SA takes responsibility for the paper as a whole.

Funding and support: By *Annals* policy, all authors are required to disclose any and all commercial, financial, and other relationships in any way related to the subject of this article as per ICMJE conflict of interest guidelines (see www.icmje.org). The authors have stated that no such relationships exist.

Publication dates: Received for publication April 4, 2014. Revisions received August 29, 2014; September 27, 2014; and October 2, 2014. Accepted for publication October 21, 2014.

Presented as an abstract at American Institute of Ultrasound in Medicine annual convention, March 2010, San Diego, CA.

REFERENCES

1. Goodacre S, Sampson F, Thomas S, et al. Systematic review and meta-analysis of the diagnostic accuracy of ultrasonography for deep vein thrombosis. *BMC Med Imaging*. 2005;5:6.
2. American Institute of Ultrasound in Medicine. Practice guidelines. Available at: <http://www.aium.org/resources/guidelines/peripheralVenous.pdf>. Published 2010. Accessed August 23, 2014.
3. Pomero F, Dentali F, Borretta V, et al. Accuracy of emergency physician-performed ultrasonography in the diagnosis of deep-vein thrombosis. A systematic review and meta-analysis. *Thromb Haemost*. 2013;109:137-145.
4. Crisp JG, Lovato LM, Jang TB. Compression ultrasonography of the lower extremity with portable vascular ultrasonography can accurately detect deep venous thrombosis in the emergency department. *Ann Emerg Med*. 2010;56:601-606.
5. Abbasi FA, Naeem S, Anwar A, et al. Two-point compression ultrasonography for lower extremity deep venous thrombosis in comparison to whole-leg Duplex ultrasonography. *JRMC*. 2013;17:57-59.
6. Abbasi S, Bolverdi E, Zare MA, et al. Comparison of diagnostic value of conventional ultrasonography by emergency physicians with Doppler ultrasonography by radiology physicians for diagnosis of deep vein thrombosis. *J Pak Med Assoc*. 2012;62:461-465.
7. American College of Emergency Physicians. Emergency ultrasound guidelines. *Ann Emerg Med*. 2009;53:550-570.
8. Ashar T, Jayarama K, Yun R. Bedside ultrasound for detection of deep vein thrombosis: the two-point compression method. *Israeli J Emerg Med*. 2006;6:36-43.
9. Bernardi E, Camporese G, Buller HR, et al. Serial 2-point ultrasonography plus D-dimer vs. whole-leg color-coded Doppler ultrasonography for diagnosing suspected symptomatic deep vein thrombosis: a randomized controlled trial. *JAMA*. 2008;300:1653-1659.
10. McIlrath ST, Blaivas M, Lyon M. Patient follow-up after negative lower extremity bedside ultrasound for deep venous thrombosis in the ED. *Am J Emerg Med*. 2006;24:325-328.
11. Tita-Nwa F, Bos A, Adjei A, et al. Correlates of D-dimer in older persons. *Ageing Clin Exp Res*. 2010;22:20-23.
12. Cogo A, Lensing AW, Prandoni P, et al. Distribution of thrombosis in patients with symptomatic deep vein thrombosis. Implications for simplifying the diagnostic process with compression ultrasound. *Arch Intern Med*. 1993;153:2777-2780.
13. Frederick MG, Hertzberg BS, Kliever MA, et al. Can the US examination for lower extremity deep venous thrombosis be abbreviated? a prospective study of 755 examinations. *Radiology*. 1996;199:45-47.
14. Maki DD, Kumar N, Nguyen B, et al. Distribution of thrombi in acute lower extremity deep venous thrombosis: implications for sonography and CT and MR venography. *AJR Am J Roentgenol*. 2000;175:1299-1301.